

# A New Vaginal Speculum and an Inexpensive Kit to Screen and Treat Dysplasia and Cancer of the Cervix

Jean M. Bouquet<sup>1\*</sup>, Andrea Chernau<sup>2</sup>, Rachel McLaughlin<sup>2</sup> and Qamrul Choudhury<sup>3</sup>

<sup>1</sup>Department of Family Medicine, Rocky Vista University, USA; <sup>2</sup>OMS II, Rocky Vista University, USA; <sup>3</sup>Department of Biomedical Sciences, Rocky Vista University, USA

## ABSTRACT

Cervical cancer is a leading cause of death in many developing countries. This is attributed to a lack of accessible screening, suboptimal medical equipment, and patient-perceived discomfort. The Bouquet Speculum TM is a novel, 5-petaled vaginal speculum that overcomes the limitations of the existing 2-bladed speculum. The current vaginal speculum, in some cases, does not allow for complete visualization of the cervix because of its design. Even seasoned veterans have difficulty with lateral vaginal wall collapse that may obscure the view of the cervix. Additionally, the radial opening of this new 5-petaled speculum distributes the forces symmetrically as opposed to the vertical forces with the 2-bladed speculum. This results in a more comfortable exam for the patients. In a survey of women who had PAP tests using the Bouquet Speculum TM, they reported, "much quicker exam with less pain." This novel speculum has been combined into a kit that screens and treats cervical cancer and dysplasia. The Cervical Cancer Cure Kit is inexpensive at \$7.50/woman. This is a cost-effective solution to treating cervical cancer in low-to-medium income countries, where the need is the greatest. By partnering with Project C.U.R.E., the kits were distributed internationally, providing screenings to hundreds of women. This novel, 5-petal vaginal speculum and Cervical Cancer Kit may be the solution to obtaining universal cervical cancer screening by providing better visualization of the cervix, ease-of-use for the provider, and greater comfort for the patient.

**Keywords:** Bacteria; Decolorization; Dye; Tannery effluent

## INTRODUCTION

Cervical cancer kills over 260,000 women every year [1]. As the second most common cancer affecting women in developing countries, it results in significant morbidity and a negative economic impact to communities [2]. Human Papilloma Virus (HPV) is the single most important risk factor for cervical cancer. HPV is responsible for all types of cervical carcinoma, including squamous, adenocarcinoma, adenosquamous, and neuroendocrine [3]. Routine gynecological screenings are effective in preventing cervical cancer, and there is a high cure rate if detected early [4,5]. Unfortunately, there is a significant lack of screening in developing countries. Some of the reasons include inadequate awareness about cervical cancer, inaccessibility to health clinics and/or female providers, and perceived embarrassment, pain, and discomfort from the procedure [6]. In some instances, the current 2-bladed speculum creates an additional barrier to effective screening by

failing to provide full cervical visibility due to anatomical variation or vaginal prolapse and by causing patient discomfort and apprehensiveness [7,8]. As the oldest instrument in the history of obstetrics, the vaginal speculum has not changed from a 2-bladed/bi-valved design in hundreds of years [9] (Figure 1).

## OBJECTIVE

Our objective is to introduce and implement a new speculum that will improve visualization of the uterine cervix, increase efficiency for the provider, and minimize discomfort to the patient. Additionally, our aim is to implement this novel speculum into an easy-to-use cervical cancer screening and treatment kit that will be distributed for use in underserved areas, nationally and internationally. Currently, there is no inexpensive "kit" to screen and treat cervical dysplasia and cancer and the current 2-bladed speculum has limitations and barriers to screening, especially in low-resource countries. This new, disposable vaginal speculum is

\*Corresponding author: Jean M. Bouquet, D.O., Assistant Professor, Family Medicine, Rocky Vista University, 8401 S. Chambers Road, Parker, CO-80134, USA, Telephone: (720) 795-9721; E-mail: jbouquet@rvu.edu

Received: May 20, 2019; Accepted: June 28, 2019; Published: July 05, 2019

Citation: Bouquet JM, Chernau A, McLaughlin R, Choudhury Q (2019) A New Vaginal Speculum and an Inexpensive Kit to Screen and Treat Dysplasia and Cancer of the Cervix. J Women's Health Care 8:470. doi: 10.35248/2167-0420.19.8.470.

Copyright: © 2019 Bouquet JM, et al. This is an open-access article distributed under the terms of the Creative Commons Attribution License, which permits unrestricted use, distribution, and reproduction in any medium, provided the original author and source are credited.

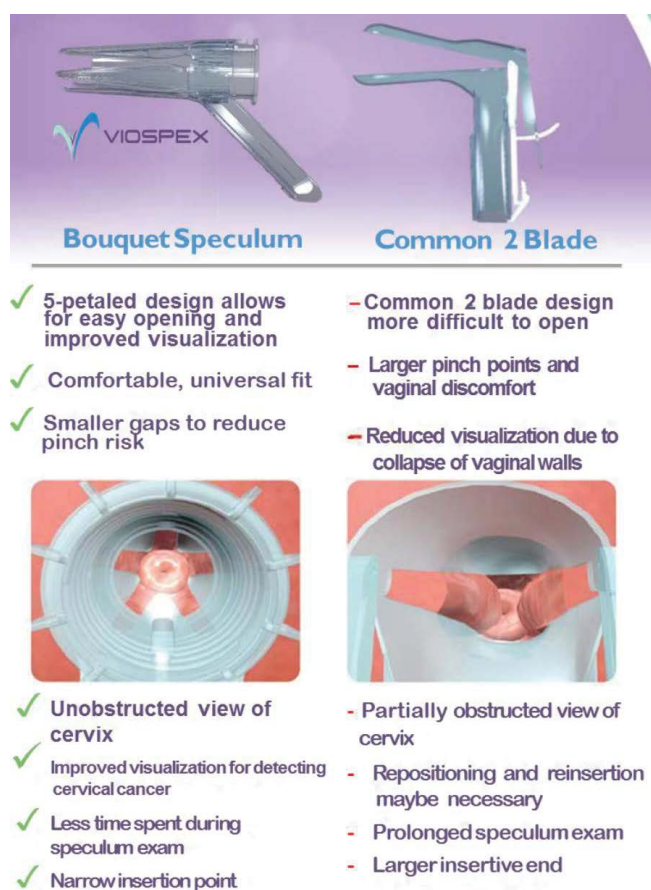


Figure 1: Comparison of 5-petaled vs. 2-bladed speculum.

less expensive than our competitors and designed with an oblique handle that can be used on any cot, bunk, bed or table. It is not necessary to have a designated gynaecology table with foot rests. This makes it a great tool to screen women in low-resource countries.

## METHOD

Dr. Jean Bouquet designed, patented, and manufactured this FDA-approved 5-petal vaginal speculum that opens in a radial fashion. A Cervical Cancer Cure Kit was designed that included the Bouquet speculum, acetic acid (5%), Medical Freeze™ (for cryotherapy), lubricant, large cotton swabs, and gloves. This kit allowed for screening of pre-cancerous and cancerous cells produced by HPV infection through visual inspection with acetic acid (VIA) and treatment with cryotherapy. The Bouquet Speculum™ was gently inserted into the vaginal canal until the speculum contacted the cervix. The dilator was advanced until desired opening for full visualization of the cervix. Acetic acid was applied to the cervix using a cotton swab. The cervix was examined for any acetowhite lesions after 45 seconds. If an acetowhite lesion was present, cryotherapy was indicated. A large cotton swab was sprayed with the Medical Freeze™ and applied to the acetowhite lesion for 45 seconds. The Bouquet Speculum™ was gently removed and discarded. The kits were distributed on medical mission trips to Peru, Paraguay, and Panama. Several kits were also utilized in Colorado along with a survey for the provider and patients who trialed the Bouquet speculum. VIA is equivalent to a Papanicolaou test (Pap smear) for cervical cancer screening. VIA has a sensitivity of 89%, specificity of 87%, and accuracy of 87% compared to a Pap smear with 52%, 95%, 95% respectively [10]. VIA can be done

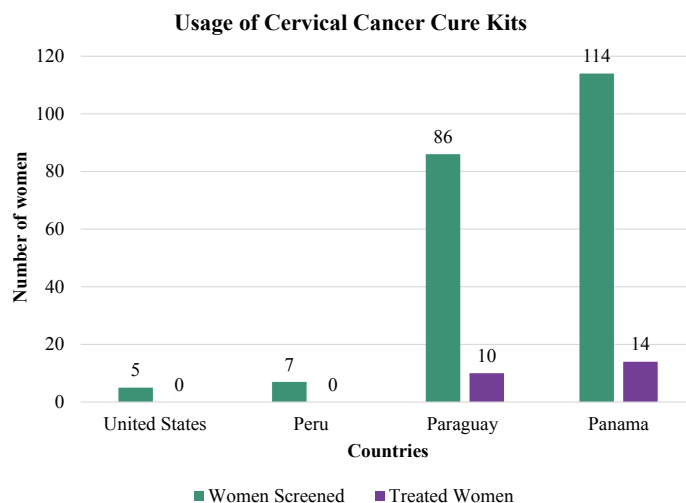


Figure 2: Screening and treatment of cervical cancer.

at the point of care (POC) and costs under \$3(USA)/woman. A PAP test has to be sent out for review by a pathologist and can't be done at the POC. The cost of a PAP with a physical and pathology reading is between \$300-400 (USA) (Figure 2).

## RESULTS AND DISCUSSION

The FDA approved the Bouquet speculum in 2015. In 2018, the first large product shipment arrived in Colorado for international distribution. A total of 212 women (n=5, Colorado, n=7 Peru, n=86 Paraguay, n=114 Panama) were screened with the Cervical Cancer Cure Kit. 24 out of 212 were positive for acetowhite lesions (14/114 in Panama, 10/86 in Paraguay, 0/7 in Peru, 0/5 in Colorado) and were subsequently treated with cryotherapy. One physician and 5 patients in Colorado completed the qualitative survey. The physician reported a 4/5 for ease-of-use and a 5/5 for visualization of the cervix.

## CONCLUSION AND FUTURE STUDIES

Future studies are needed to directly compare the Bouquet Speculum™ to the current 2-bladed speculum. These studies should include quantitative assessments of visualization of cervix, ease-of-use by the provider, and comfort of the patient. A randomized, blinded group will receive their PAP tests with the 2-bladed speculum (one arm of the study), the other will receive their PAPs using the 5-petaled Bouquet Speculum™ (second arm). The provider will answer two survey questions using the Likert Scale (ease-of-use and visibility of the cervix). The patient will answer one survey question using the Likert Scale rating the relative comfort of the speculum. This study proposal will be submitted to the Rocky Vista University, Institutional Review Board (IRB) shortly.

## REFERENCES

1. Torre LA, Islami F, Siegel RL, Ward EM, Jemal A. Global cancer in women: Burden and trends. *Cancer Epidemiol Biomarkers Prev.* 2017;26(4):444-457.
2. Goldie SJ, Gaffikin L, Goldhaber-Fiebert J, Gordillo-Tobar A, Levin C, Mahe C, et al. Cost-effectiveness of cervical-cancer screening in five developing countries. *N Engl J Med.* 2005;353(20):2158-2168.
3. Cutts FT, Francheschi S, Goldie S, Castellsague X, De Sanjose S, Garnett G, et al. Human papilloma virus and HPV vaccines. *Bull World Health Organ.* 2007;85(9):719-726.
4. Nakagawa JT, Espinosa MM, Barbieri M, Schirmer J. Cervical

- carcinoma: Survival rate and prognostic factors in women in the state of Mato Grosso. *Acta Paulista de Enfermagem*. 2011;24(5): 631-637.
5. Carneiro SR, Fagundes MDA, Do Rosário PDJO, Neves LMT, Souza GDS, Pinheiro MDCN. Five-year survival and associated factors in women treated for cervical cancer at a reference hospital in the Brazilian Amazon. *PLoS ONE*. 2017;12(11):e0187579.
  6. Seng LM, Rosman NA, Khan A, Md Haris N, Mustapha NAS, Husaini NSM, et al. Awareness of cervical cancer among women in Malaysia. *Int J Health Sci*. 2018;12(4):42-48.
  7. Bates CK, Carroll N, Potter J. The challenging pelvic examination. *J Gen Intern Med*. 2001;26(6):651-657.
  8. Asiedu MN, Agudogo J, Krieger MS, Miros R, Proeschold-Bell RJ, Schmitt JW, et al. Design and preliminary analysis of a vaginal inserter for speculum-free cervical cancer screening. *PLoS One*. 2017;12(5):e0177782.
  9. Sandelowski M. This most dangerous instrument propriety, power, and the vaginal speculum. *Journal of Obstetrics Gyn and Neo Nursing*. 2000;29(1):73-82.
  10. Bhattacharyya AK, Nath JD, Deka H. Comparative study between pap smear and visual inspection with acetic acid (VIA) in screening of CIN and early cervical cancer. *Journal of Mid-Life Health*. 2015;6(2):53-58.